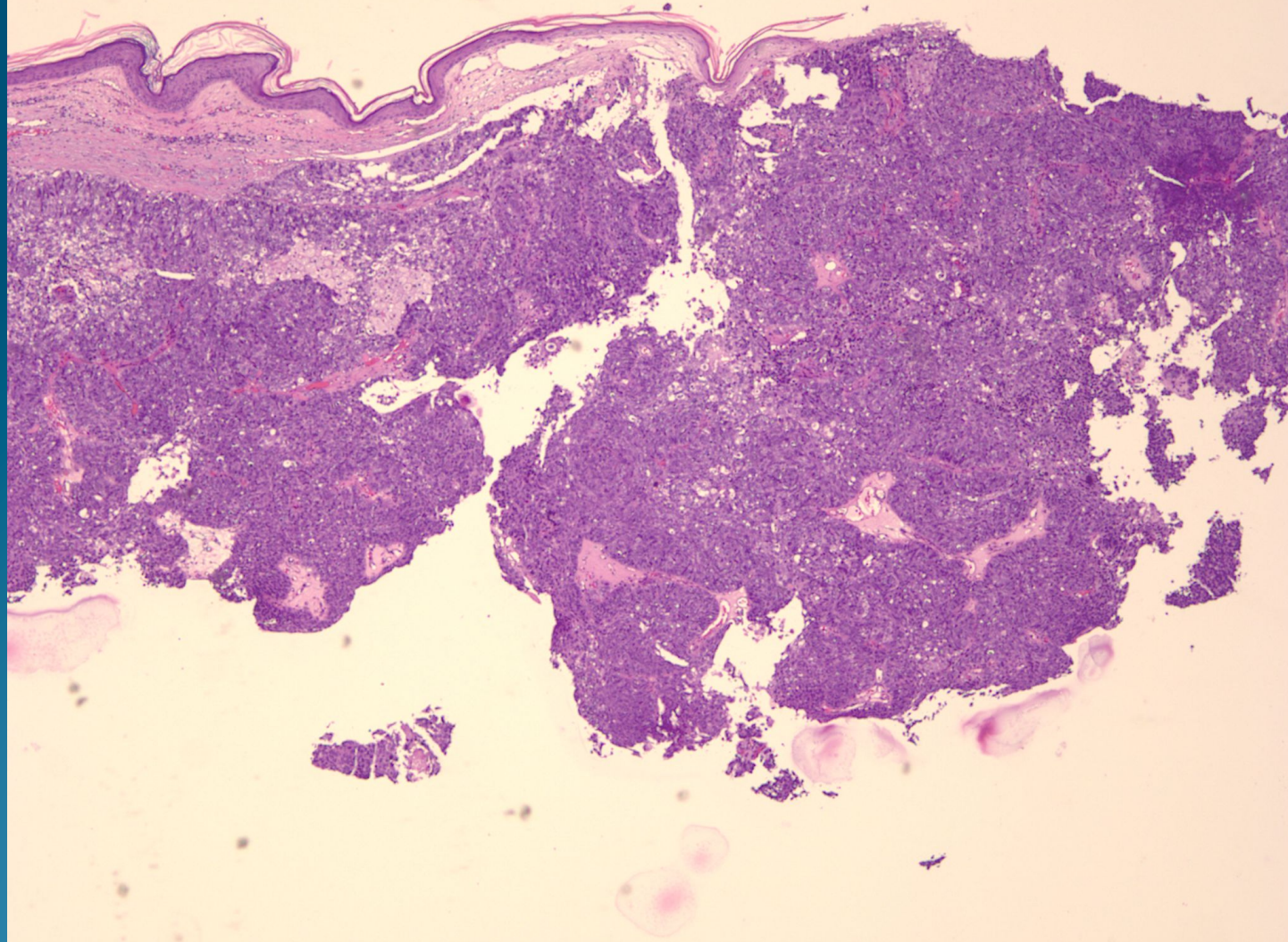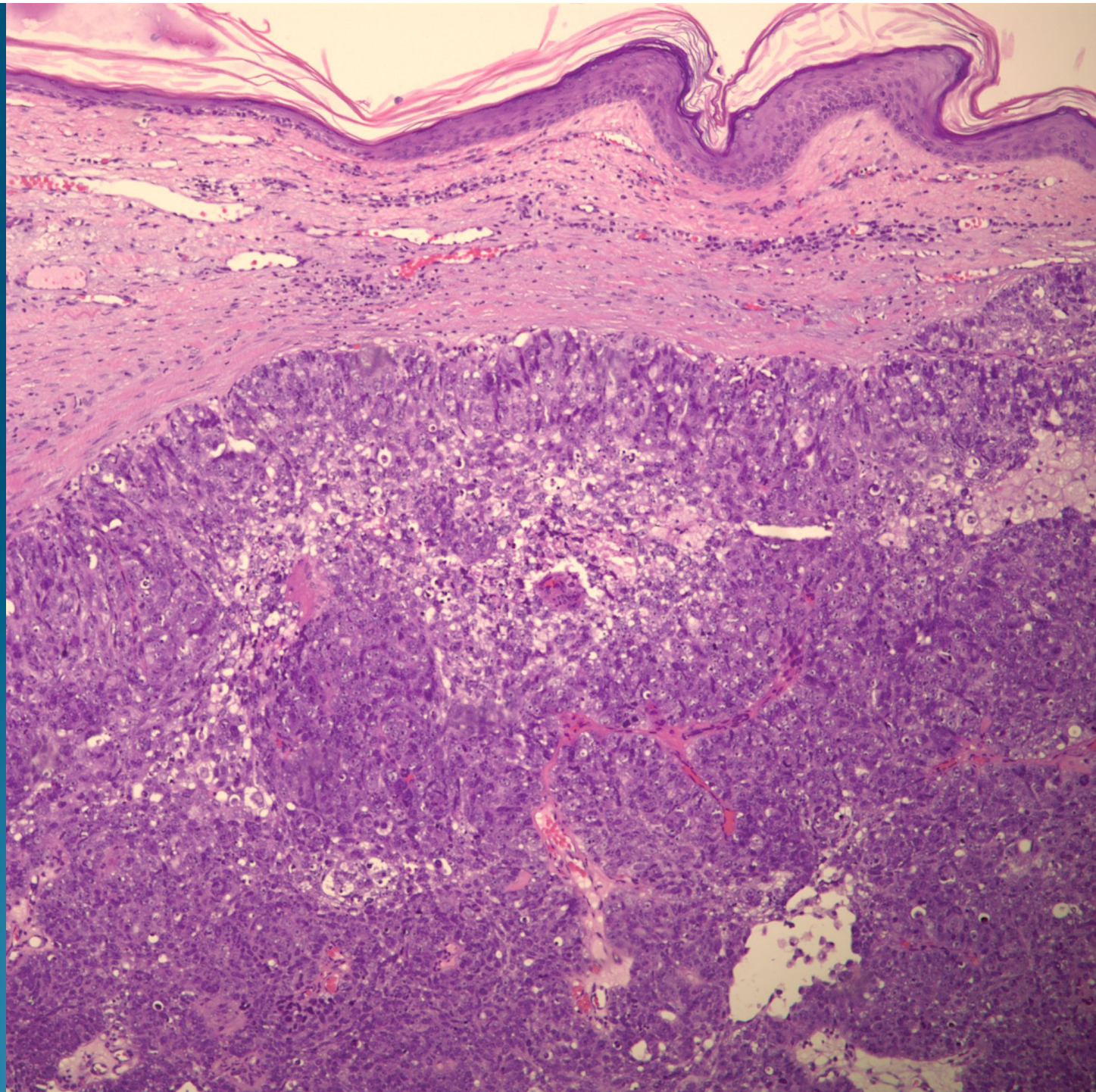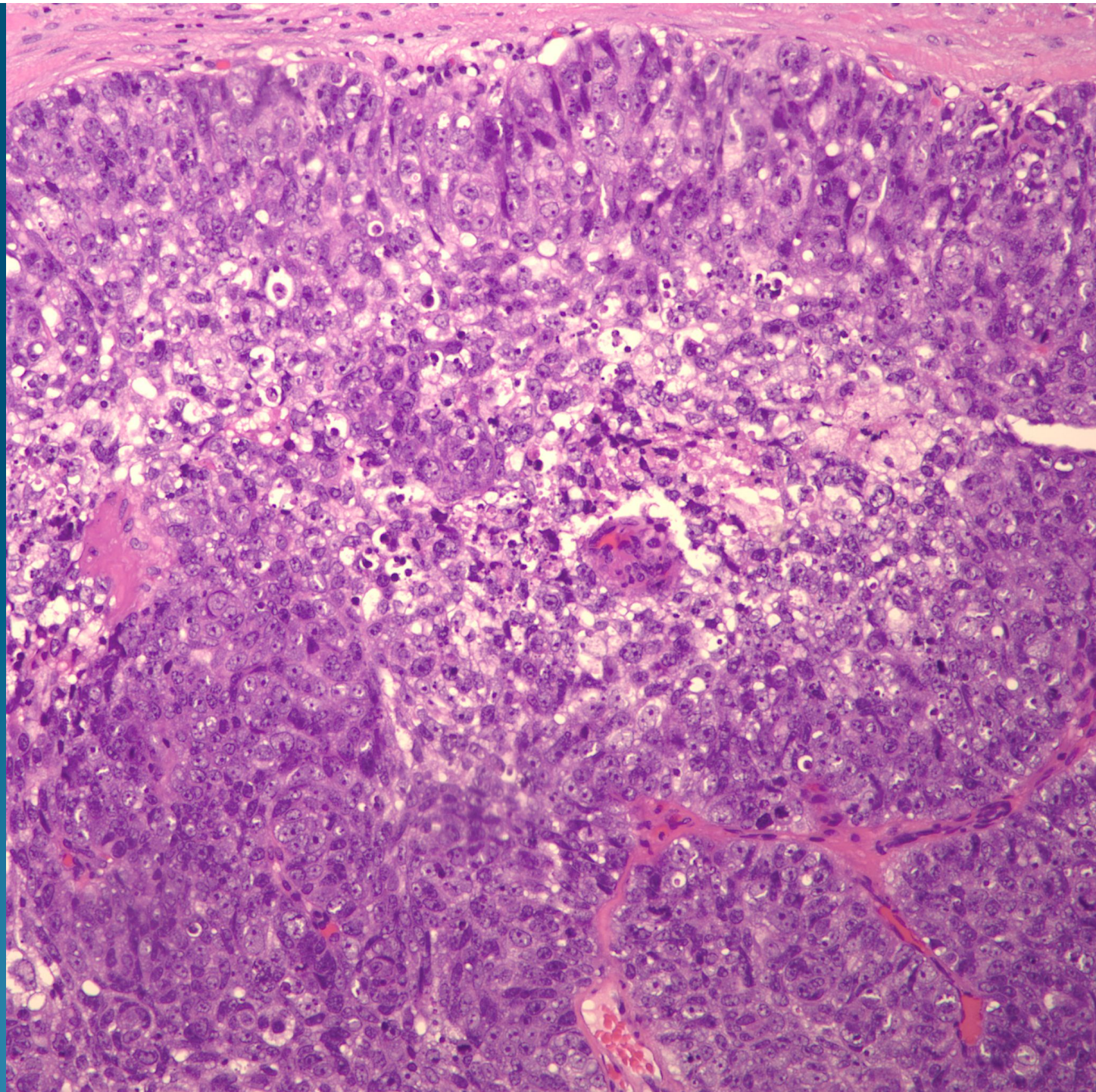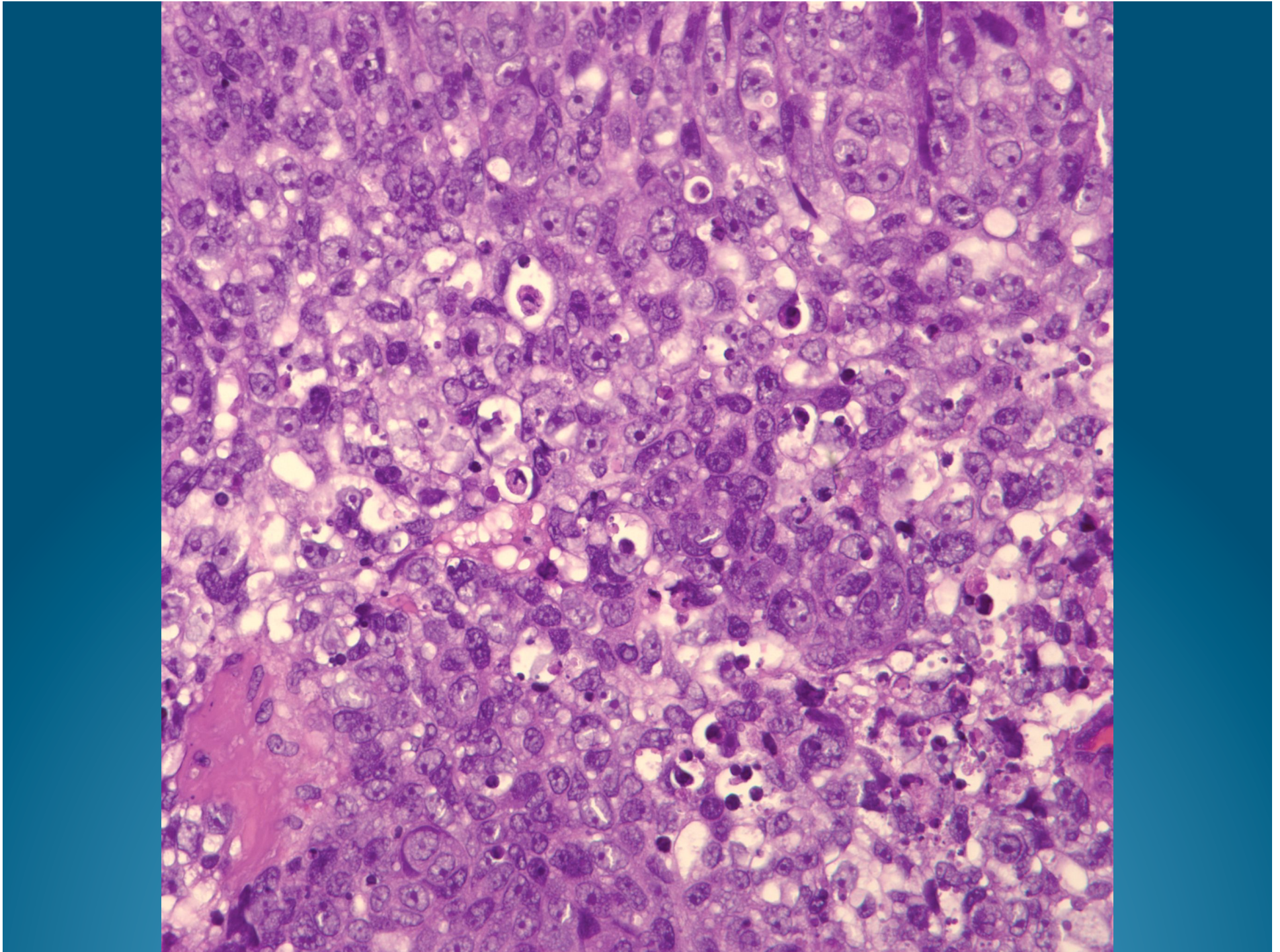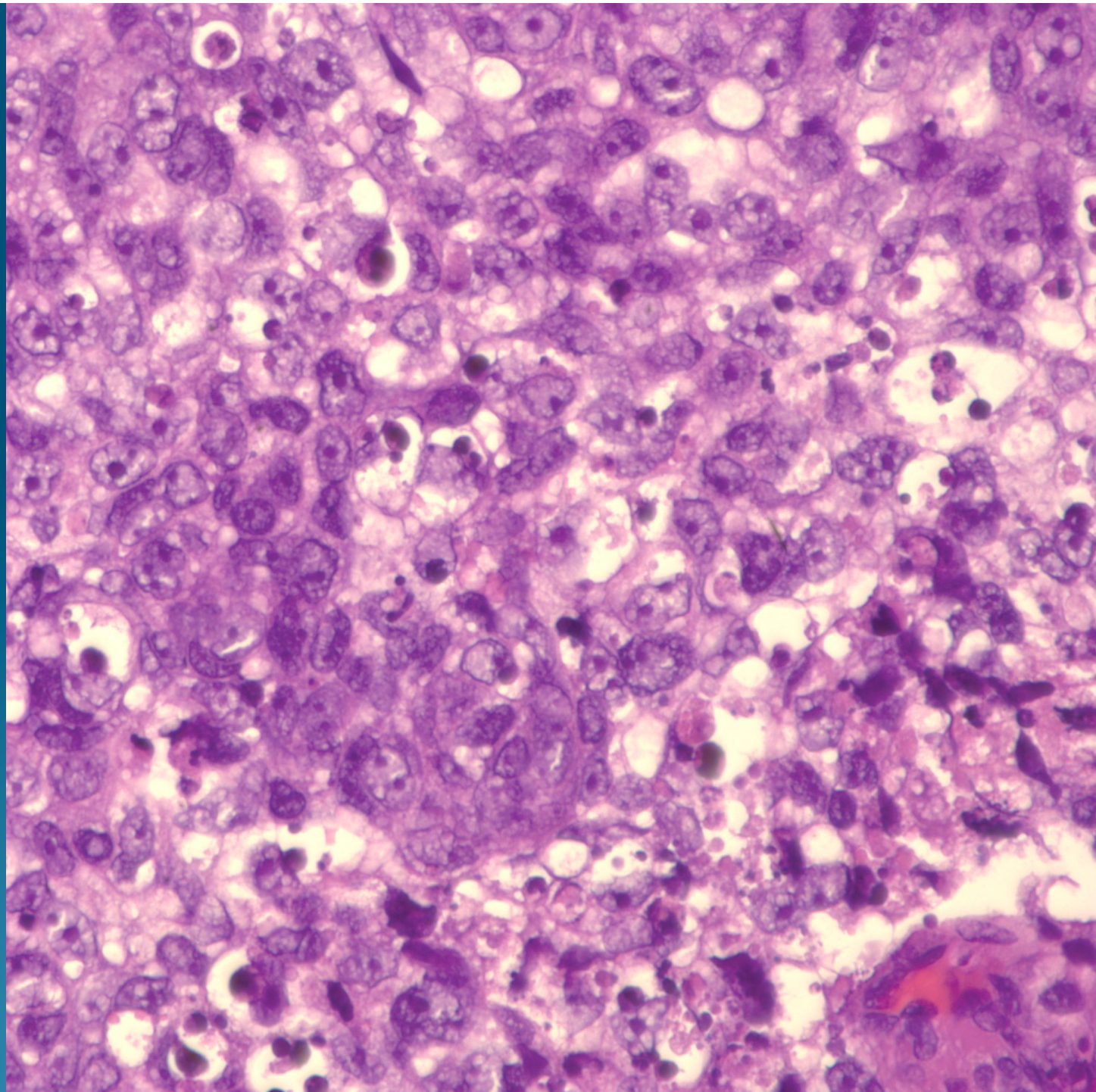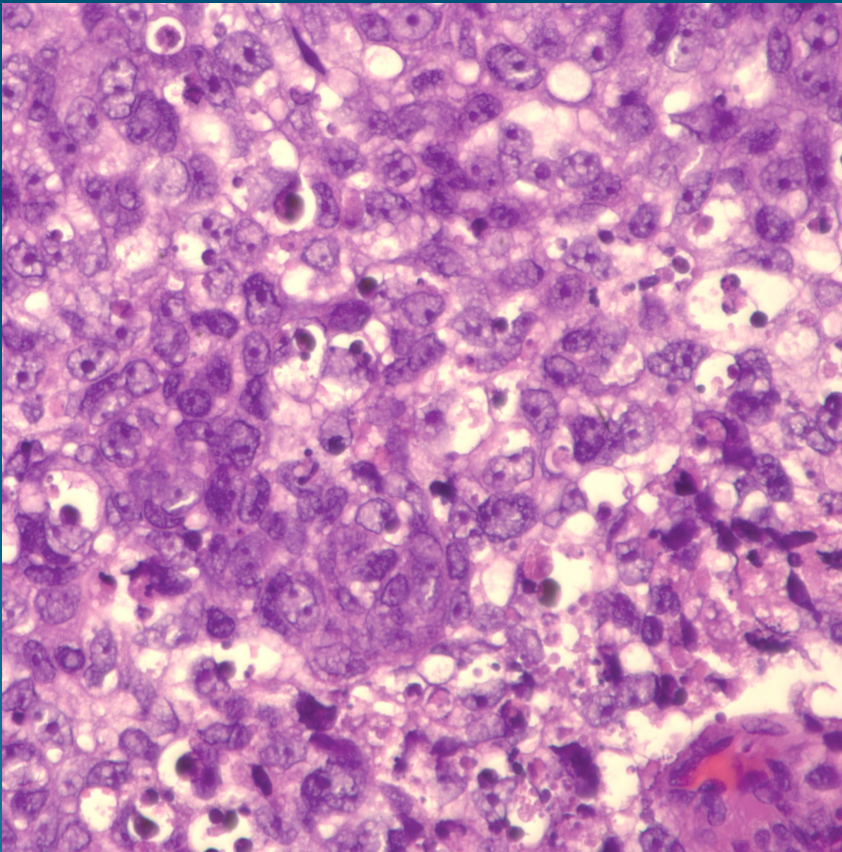


What is the best diagnosis?

- A. Eccrine spiradenoma
- B. Apocrine carcinoma
- C. Sebaceous carcinoma
- D. Pilomatricoma
- E. Metastatic renal cell carcinoma

Sebaceous Carcinoma, Poorly Differentiated

Pearls



- Poorly differentiated basophilic cells with vacuolated cytoplasm representing sebaceous changes
- Lack true peripheral palisading
- May have focal squamous differentiation
- Numerous atypical mitotic figures